
CASE REPORT**A Case Report of Atypical Presentation of Multiple Myeloma on Serum Protein Electrophoresis**

Pooja P. Padasali¹, Anil Malleshappa^{1}*

¹Department of Clinical Biochemistry, KLE's Dr Prabhakar Kore Hospital & MRC, Hi-tech Laboratory, Belagavi-590010 (Karnataka) India

Abstract:

Multiple myeloma is a group of B-cell disorders resulting in the secretion of a specific and unique monoclonal immunoglobulin (M-protein). Protein electrophoresis is advised whenever multiple myeloma is suspected. The M-protein usually migrates in the gamma or beta region of the normal protein pattern; very rarely it may appear in the alpha 2 or even in alpha 1 region. We report a rare case of multiple myeloma with biclonalgammopathy in 50 year old women who presented with generalised weakness, swelling over chest and lower back pain. Atypical case presentation where the patient with multiple myeloma presented with two M-spike in beta-globulin region on protein electrophoresis with hypoglobulinemia. To reveal the nature of M bands or clonality, serum Immunofixation study was performed which revealed IgA with kappa and IgM with kappa light chains. Such pattern is very rare if we consider the various immunofixation patterns observed in different gammopathies.

Keywords: Multiple myeloma, Biclonalgammopathy, Immunofixation

Introduction:

Biclonalgammopathy is characterized by simultaneous appearance of two different M-components. The incidence is about 1–2.5% of all monoclonal gammopathy. Biclonalgammopathies are a group of disorders characterized by the production of 2 distinct monoclonal proteins. The presence of 2 monoclonal proteins may be because of the proliferation of 2 clones of plasma cells,

each producing an unrelated monoclonal immunoglobulin, or it may result from the production of 2 monoclonal proteins by a single clone of plasma cells. Biclonalgammopathies are more symptomatic than monoclonal gammopathy.

Case Report:

A 50 year old woman was admitted to the hospital for backpain. The patient was in good health until 1 month before, when she felt backpain. The quality of pain was dull, progressive and increased on walking. Thereafter the backpain and weakness steadily progressed with nausea and loss of appetite. Physical examination was unremarkable except for slight tenderness on the lower back and chest.

The laboratory tests revealed an erythrocyte sedimentation rate of 120 mm/hour and hemoglobin of 7 g/dl with dimorphicanemia with thrombocytopenia. Leukocyte count was 5970/cmm, platelet count 72000/cmm, RBC 2.5million/ cmm. Peripheral blood smear showed marked rouleaux formation. Serum creatinine was 1.6mg/dl, urea 39 mg/dl and serum electrolytes were normal, except for high serum calcium of 11.3 mg/dl. Urinalysis showed strongly positive proteinuria (+++), with Bence-Jones protein was negative. Total protein-9.0, albumin-2.0 and A/G ratio- 0.2, serum amylase-115 and serum lipase-190.

Bone marrow examination showed increased plasma cells with binucleate and trinucleate forms seen. Plasmablasts with centrally placed nucleus, prominent 1-2 nucleoli were also seen features suggestive of multiple myeloma.

Radiograph skull showed few well defined small rounded punched out radiolucent areas noted diffusely involving the calvarium (Fig. 1). X-ray Lumbo-sacral spine revealed diffuse osteopenia noted in the visualized bones, osteophyticclippings noted in L3, L4 and L5 vertebral bodies (Fig. 2).

MRI screening of entire spine (plain) showed generalised decrease in bone density, multiple wedge compression fractures involving D5, L2, L3 and L4 vertebral bodies and evidence disc bulges at the level of L4-L5 and L5-S1 with focal annular fissure at level L5-S1 causing compression on subarachnoid space.

Serum protein electrophoresis showed a total protein of 10.2 g/dl, with reduced albumin with increase in beta1 and beta 2 globulins and spike pattern of beta-1 globulin was 6.0 g/d, (normal range of 0.5 – 0.8 g/dl), and beta-2 globulin was 1.6 g/dl, (normal range of 0.3-0.7 g/dl). Gamma-globulins were reduced with 0.2 g/dl, (normal range 0.8 – 1.8g/dl). Serum protein electrophoresis on capillary electrophoresis revealed two sharp discrete bands in the beta-1 and beta-2 globulin regions.

Immunofixation electrophoresis revealed the presence of biclonal gammopathy (IgA kappa and IgM kappa).

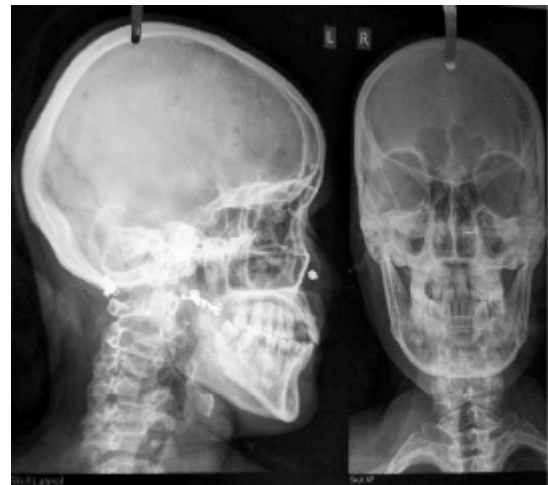

Fig. 1: X-ray Skull AP/Lateral: Well Defined Small Rounded Punched Out Radiolucent Areas Noted Diffusely Involving the Calvarium

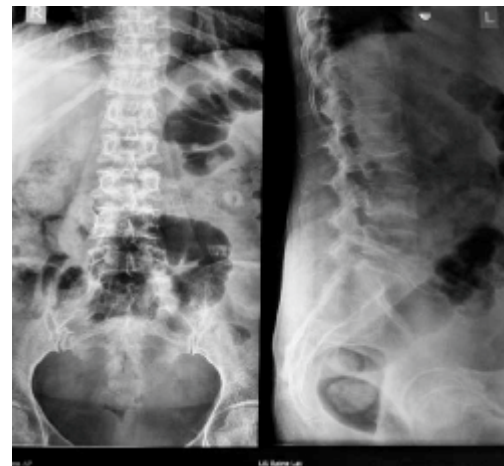


Fig. 2: X- ray Lumbosacral Spine AP/Lateral: Osteophyticclippings Noted in L3, L4 and L5 Vertebral Bodies

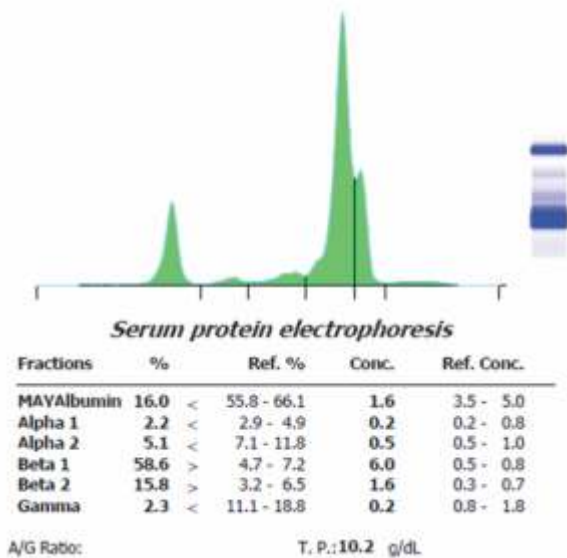


Fig.3: Serum Protein Electrophoresis: Albumin is Reduced with Increase in Beta Globulins with Two Sharp Discrete Bands in the β_1 and β_2 Globulin Regions and Reduced Gamma Globulins

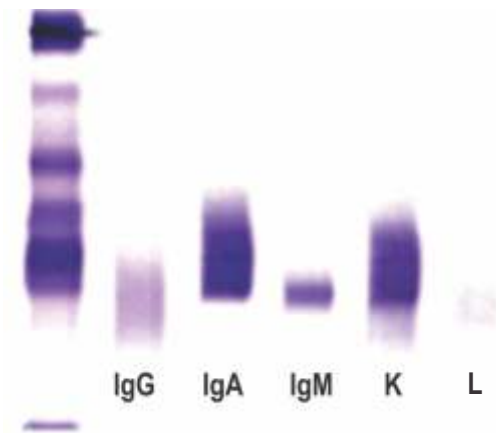


Fig.4: Immunofixation Electrophoresis: Biclonal Gammopathy (IgA kappa and IgM kappa)

Discussion:

Multiple myeloma is a neoplastic clonal disease characterised morphologically by plasma cell infiltration of the medullary space and involvement of extraosseous tissues in a multi-focal fashion [1]. Monoclonal gammopathy is a group of B cell disorders which is known for production of a specific and unique M component. However, biclonalgammopathies are defined by simultaneous appearance of different M components, two distinct or different monoclonal proteins [2]. The most commonly encountered combination is IgG and IgA (53%), followed by IgM and IgG (24%) as per literature [2,3]. According to different literature, either one monoclonal cell clone in a monoclonal gammopathy may give rise to biclonalgammopathy or else, the same may arise from two different monoclonal cell clones.

Hence, biclonalgammopathy may arise either due to independent proliferation of two separate clones of plasma cells where each clone gives rise to an unrelated monoclonal immunoglobulin or this may result from a single clone of plasma cells producing two different monoclonal proteins [4].

The diagnosis of myeloma requires

- 1) 10% or more clonal plasma cells on bone marrow examination or biopsy-proven plasmacytoma,
- 2) Presence of serum and/or urinary monoclonal protein (except in patients with true nonsecretory multiple myeloma), and
- 3) Evidence of end-organ damage (hypercalcaemia, renal insufficiency, anaemia, or bone lesions) related to the underlying plasma cell disorder [5].

The circulating M-protein may consist of an intact immunoglobulin, the light chain only, or (rarely) the heavy chain only. The heavy chain is from one

of the five immunoglobulin classes G, A, M, D or E, while the light chain is either κ (kappa) or λ (lambda) in type. It occurs as intense, narrow band most often found with the gamma-globulins, then in a diminishing frequency between gamma and the b-globulin and rarely in the beta and alpha-2 regions[6].

In our patient most of the biochemical results were suggestive of the pattern found in multiple myeloma. The patient was having high serum calcium level at time of diagnosis. Hypercalcaemia is found initially in 22–30% patient with multiple myeloma [7, 8], the exact cause of which is unknown. In the patient, the M band in the beta 1 and beta 2 regions was shown to be bound to IgA

and IgM. A biclonalgammopathy is suspected when there are two proteins with different mobilities comprising two different monoclonal heavy chains with their respective monoclonal light chains [9]. A biclonalgammopathy may also consist of two heavy chains of the same class and monoclonal light chains of the same type.

Biclonal multiple myeloma accounts for only 1-5% of all myelomas. In the case presented above, we have reported IgA kappa and IgM kappa type of biclonalgammopathy detected by appearance of two bands in the beta region on serum protein electrophoresis. The classes IgA kappa and IgM kappa were further confirmed by immunofixation.

References

- Osterborg A, Hansson LO, Mellstedt H. Immunoglobulins in multiple myeloma. In: Garhton G, Durie B (eds). Multiple myeloma. 1st ed. London: Oxford University Press 1996; 36-50.
- Osterborg A, Mellstedt H. Monoclonal and biclonal immunoglobulin producing disorders. *Eurp J* 1989;43(51):11-18.
- Kyle RA, Robinson R, Katzman J. The clinical aspects of biclonalgammopathies. *Am J Med* 1981; 71(6):999-06.
- Kim NY, Gong SJ, Kim J, Youn SM, Lee JA. Multiple myeloma with biclonalgammopathy accompanied by prostate cancer. *Korean J Lab Med* 2011; 31(4):285-89.
- Rajkumar SV. Multiple myeloma: 2011 update on diagnosis, risk stratification, and management. *Am J Hematol* 2011; 86(1):57-65.
- O'Connell TX, Horita TJ, Kasravi B. Understanding and interpreting serum protein electrophoresis. *Am Fam Physician* 2005; 71(1):105-12.
- Kyle RA. Multiple myeloma: review of 869 case. *Mayo Clin Proc* 1975; 50(1):29-40.
- Alexanian R, Balserezak S, Bonnet JD, et al. Prognostic factors in multiple myeloma. *Cancer* 1975; 36(0):1192-201.
- Bakkus MH, Schots R, Gomez La Fuente PB, et al. Clonally related IgA- and IgE-secreting plasma cells in a myeloma patient. *Eur J Haematol* 2000; 65(5):348.

***Author for Correspondence:** Dr. Anil Malleshappa, Consultant in Clinical Biochemistry, KIE's Dr PrabhakarKore Hospital &MRC, Belagavi - 590010 Email: anilsm74@yahoo.co.in Cell: 9448003165